

Academic Year 2014 – 2015

INTESTINAL VAGINOPLASTY: WHICH SHOULD BE THE BOWEL SEGMENT OF CHOICE?

Cedric ROBBENS

Promotor: Prof. Dr. Stan Monstrey

Dissertation presented in the 2nd Master year

in the programme of

Master of Medicine in Medicine

Deze pagina is niet beschikbaar omdat ze persoonsgegevens bevat.
Universiteitsbibliotheek Gent, 2021.

This page is not available because it contains personal information.
Ghent University, Library, 2021.

Deze pagina is niet beschikbaar omdat ze persoonsgegevens bevat.
Universiteitsbibliotheek Gent, 2021.

This page is not available because it contains personal information.
Ghent University, Library, 2021.

PREFACE

My thesis discusses the use of bowel segments in vaginoplasty. I have chosen this subject because of my interest in reconstructive surgery. I am very grateful for the opportunity to write this work about a topic in my field of interest.

I would like to thank all the people that helped bringing this literature review to a successful conclusion.

First of all, the promotor of this literature review Prof. Dr. Stan Monstrey for the guidance and the counseling.

My parents, Frank Robbens and Karine De Saedeleir, for giving me the chance to study and always supporting me. And finally, my sister Evy Robbens for revising this work.

I end this preface with a quote by Walt Whitman (1819 – 1892) that represents the fundamental idea of this assignment:

“That the powerful play goes on and you may contribute a verse. What will your verse be?”

Cedric Robbens

08.04.2015

TABLE OF CONTENTS

FRONT COVER

TITLE PAGE

COPYRIGHT

CONFIDENTIALITY AND ASSIGNMENT OF RIGHTS

PREFACE

TABLE OF CONTENTS

ABSTRACT – ENGLISH.....	1
ABSTRACT – NEDERLANDS.....	3
INTRODUCTION.....	5
METHODS.....	15
RESULTS.....	18
DISCUSSION.....	33
CONCLUSION.....	37
REFERENCES.....	38

ABSTRACT - ENGLISH

INTRODUCTION

Intestinal vaginoplasty is a reconstructive procedure for the vaginal canal and the vulva that can be performed in patients with congenital agenesis of the vagina, patients with disorders of sex development, male-to-female transgender patients and patients with a history of colpectomy. This reconstruction uses a free flap from the jejunum, ileum, caecum or sigmoid segment of the intestinal conduit.

METHODS

Several electronic databases, the library of the Faculty of Medicine and Health Sciences from the Ghent University and the promotor of this literature review, Prof. Dr. Stan Monstrey, were consulted for primary studies on intestinal vaginoplasty. After inclusion and exclusion, 30 articles were taken into consideration for this literature review.

OUTCOME MEASURES

Information was gathered on patients, study design, indications, patient age, surgical procedure, anatomical results, functional results, acute complications and long-term complications.

RESULTS

The selected 30 articles provided information on a total amount of 917 patients. Most studies focused on sigmoid vaginoplasty and were of a retrospective design. Procedure-related complications had a low prevalence and most of them were of a mild severity. Stenosis of the neovagina was the main long-term complication in all intestinal segments. Only one case of diversion colitis was reported while no carcinoma of the intestinal neovagina was mentioned.

DISCUSSION

It is important to emphasize that there is a significant difference in the available literature on the different bowel segments. While many qualitative studies on sigmoid vaginoplasty are published, only a few qualitative studies on jejunum, ileum and caecum vaginoplasty are available.

CONCLUSION

Based on the current evidence, intestinal vaginoplasty is associated with a low prevalence of procedure-related complications in all bowel segments. It is a safe technique and there is no superiority of one bowel segment over the other.

There is a need for qualitative prospective studies on intestinal vaginoplasty, especially concerning jejunum, ileum and caecum segments and for a uniform representation of the functional results for all bowel segments.

KEY WORDS

Intestine; Small; Large; Bowel; Jejunum; Ileum; Caecum; Sigmoid; Vaginoplasty; Vagina reconstruction; Neovagina; Literature review

ABSTRACT - NEDERLANDS

INLEIDING

Intestinale vaginoplastiek is een reconstructieve techniek voor de vagina en de vulva die kan uitgevoerd worden bij patiënten met congenitale agenesie van de vagina, patiënten met stoornissen in de seksuele ontwikkeling, man-naar-vrouw transseksuelen en patiënten met een voorgeschiedenis van colpectomie. Deze reconstructie maakt gebruik van een vrije flap van het jejunum, ileum, caecum of sigmoïd segment van het intestinaal kanaal.

METHODOLOGIE

Verschillende elektronische databases, de bibliotheek van de Faculteit Geneeskunde en Gezondheidswetenschappen van de Universiteit Gent en de promotor van deze literatuurstudie, Prof. Dr. Stan Monstrey, werden geraadpleegd voor primaire studies over intestinale vaginoplastiek. Na inclusie en exclusie werden 30 artikels in aanmerking genomen voor deze literatuurstudie.

UITKOMSTMATEN

Informatie werd verzameld over patiënten, onderzoeksopzet, indicaties, leeftijd van de patiënten, chirurgische procedure, anatomische resultaten, functionele resultaten, acute complicaties en lange termijn complicaties.

RESULTATEN

De 30 geselecteerde artikels gaven informatie over een totaal van 917 patiënten. De meeste studies concentreerden zich op sigmoïde vaginoplastiek en hadden een retrospectieve onderzoeksopzet. Procedure gerelateerde complicaties hadden een lage prevalentie en waren meestal mild. Stenose van de neovagina was de meest voorkomende lange termijn complicatie voor alle darmsegmenten. Slechts één geval van diversion colitis werd gerapporteerd terwijl er geen carcinoom van de intestinale neovagina werd vermeld.

DISCUSSIE

Het is belangrijk te benadrukken dat er een aanzienlijk verschil is in de beschikbare literatuur voor de verschillende darmsegmenten. Terwijl er veel kwalitatieve studies over sigmoïde vaginoplastiek gepubliceerd zijn, zijn er maar een paar kwalitatieve studies over jejunum, ileum en caecum vaginoplastiek beschikbaar.

CONCLUSIE

Gebaseerd op de huidige wetenschappelijke kennis is intestinale vaginoplastiek geassocieerd met een lage prevalentie van procedure gerelateerde complicaties. Het is een veilige techniek en er is geen superioriteit van één darmsegment over het andere.

Er is nood aan kwalitatieve prospectieve studies over intestinale vaginoplastiek, vooral betreffende jejunum, ileum en caecum segmenten en aan een uniforme weergave van de functionele resultaten voor alle darmsegmenten.

TREFWOORDEN

Intestinaal; Dunne darm; Dikke darm; Jejunum; Ileum; Caecum; Sigmoid; Vaginoplastiek; Vagina reconstructie; Neovagina; Literatuurstudie

INTRODUCTION

Vaginoplasty is a reconstructive procedure for the vaginal canal and the vulva that can be performed in various clinical situations.

The most common indication is congenital agenesis of the vagina, also known as Müllerian agenesis or *Mayer-Rokitansky-Küster-Hauser syndrome (MRKH)*. It is caused by embryologic growth failure of the müllerian duct, with resultant agenesis or underdevelopment of the vagina, uterus, or both. The vaginal canal is absent or markedly shortened. The ovaries, given their separate embryologic source, are normal in structure and function [1,2].

Women with Müllerian agenesis have a normal 46,XX karyotype and a normal hormonal profile. The frequency of congenital absence of vagina and uterus is not yet entirely clear. Reported incidences vary from 1 in 4,000 to 5,000 female births. Although the vast majority of cases of MRKH seem to be sporadic, familial aggregates have been reported [3].

Adolescent girls with Müllerian agenesis typically present with primary amenorrhea along with a normal growth and development. After gonadal dysgenesis, Müllerian agenesis is the second most common cause of primary amenorrhea. On physical examination, patients with Müllerian agenesis have normal height, secondary sexual characteristics, body hair, and external genitalia. Furthermore, a vagina is either absent or present as a short blind-ended structure without a cervix at the vaginal apex [1].

Conventional transabdominal, translabial, or transrectal ultrasonography; three-dimensional ultrasonography; and magnetic resonance imaging can be used to evaluate the Müllerian structures and are helpful in definitively characterizing anatomy [1].

There appear to be two subtypes of MRKH: the typical and the atypical with the frequency of the latter being much greater. The typical form is characterized by laparoscopic or laparotomic findings of symmetric muscular buds (the Müllerian remnants) and normal Fallopian tubes; this is referred to as the so-called Rokitansky sequence, where only the caudal part of the Müllerian duct (upper vagina and uterus) is affected. The atypical form shows, in addition, asymmetric hypoplasia of one or two buds, with or without dysplasia of the Fallopian tubes: this is often associated with other anomalies, including mainly renal defects, cervico-thoracic and, to a minor extent, hearing defects and digital anomalies of varying severities. Cases of MRKH have rarely been associated with neoplasia in the female

genital tract. Patients with tumors arising outside the female genital tract are unusual. Very rare cases of leiomyoma and glioblastoma have been reported [3-5].

A young woman's sense of well-being and quality of life are impacted by the condition. Affected individuals without treatment will find it difficult, if not impossible, to engage in penile-vaginal intercourse, they do not menstruate, and they will be unable to carry a pregnancy. The discovery that sexual intercourse will not occur without medical intervention and the realization of absence of childbearing capacity may be devastating to an adolescent who has not yet reached certain developmental milestones. Because of physical and psychological challenges, it has been suggested that the management of MRKH falls into two categories: (1) the need to anatomically manage the anomaly so that young women may have the option to engage more easily in penile-vaginal intercourse and (2) the need to help young women cope with the psychological impact of the condition [6].

A second indication are *disorders of sex development (DSD)*. These are defined as congenital conditions in which development of chromosomal, gonadal, or anatomical sex is atypical [7]. DSD is an umbrella term for a large amount of medical conditions involving the reproductive system of which the most common are Congenital Adrenal Hyperplasia (CAH) and Androgen Insensitivity Syndrome (AIS). DSD replaces terms like 'intersex', 'pseudohermaphroditism (PH)', 'hermaphroditism' and 'sex reversal', which are often perceived as pejorative by patients and can be confusing to both health professionals and parents. This idea was published in a consensus statement by the Lawson Wilkins Pediatric Endocrine Society (LWPES) and the European Society for Paediatric Endocrinology (ESPE) in 2006 [8-10].

A DSD patient may require gender-corrective surgery of external and internal genitalia, removal of part or whole of dysgenetic gonads or ovotestes and possible relocation of gonads, and hormonal replacement starting in infancy or adolescence and extending into adulthood [11].

The most common DSD is Congenital Adrenal Hyperplasia (CAH). It is a group of autosomal recessive disorders resulting from the deficiency of one of the five enzymes required for the synthesis of cortisol in the adrenal cortex. The most frequent is steroid 21-hydroxylase deficiency, accounting for more than 90 percent of cases. Clinical manifestations include salt wasting, ambiguous genitalia, postnatal virilization, affected linear growth and problems with reproductive function [12].

The clinical management of CAH initially involves suppression of adrenal androgen production with supraphysiological doses of glucocorticoid drugs, in addition to treatment of adrenal insufficiency. Once epiphyseal closure has occurred and growth regulation is no longer a concern, a shift in treatment goals from optimisation of growth and development to prevention of long-term adverse outcomes and optimisation of fertility and sexual function is needed [13].

Another common DSD is Androgen Insensitivity Syndrome (AIS). It is typically characterized by evidence of feminization (i.e., undermasculinization) of the external genitalia at birth, abnormal secondary sexual development in puberty, and infertility in individuals with a 46,XY karyotype. AIS represents a spectrum of defects in androgen action and can be subdivided into three broad phenotypes:

- Complete androgen insensitivity syndrome (CAIS), with typical female external genitalia.
- Partial androgen insensitivity syndrome (PAIS) with predominantly female, predominantly male, or ambiguous external genitalia.
- Mild androgen insensitivity syndrome (MAIS) with typical male external genitalia.

A short blind ending vagina can be seen, particularly in CAIS [14,15]. This subtype results from a defect in the androgen receptor, so that the end organ tissue does not respond appropriately to androgenic signaling. These 46,XY individuals are phenotypic females who may present in early childhood when testes are found on imaging or during surgical procedures such as hernia repair. However, they are more commonly diagnosed in adolescence after presenting with primary amenorrhea [16].

A delayed approach to gonadectomy and vaginal reconstruction represents the best strategy. The risks of malignancy and psychological effects of being anatomically abnormal are minimal and outweighed by the benefits of avoiding early hormone replacement and lessening surgical risks from vaginoplasty [16].

A third indication are patients with pelvic tumors or traumatic injuries in which *colpectomy* has been performed.

Radical surgery including partial or total colpectomy is sometimes inevitable in the management of gynecological malignancies, such as cervical, vaginal and endometrial cancer. Furthermore, radiotherapeutic interventions such as percutaneous irradiation and vaginal

brachytherapy have additional negative effects on the vaginal mucosa and pelvic floor and can compromise the quality of life, the physical and psychological integrity as well as the body image and the sexuality of the patients [17].

Conditions that impair microvasculature such as diabetes, hypertension and smoking are associated with an increased incidence and severity of early and late complications after radiation treatment. Especially smoking is associated with a worse overall survival in women with cervical and vulvar cancers and is a strong predictor for radiation treatment complications [18].

Radiotherapy injury is a complex process. Radiation changes endothelial cells, activates the coagulation system, has direct inflammatory effects, suppresses the inflammatory response, and causes epithelial injury [18].

Various studies have described the strong interferences between the genital cancer treatment modalities and the patient's quality of life, especially in terms of sexuality, attractiveness and body image, not only due to vaginal stenosis and shortness, but also due to the fatigue, worries about the patients' family and fear of cancer recurrence. Vagina reconstruction is a safe procedure for gynecologic cancer patients and should be offered by radical pelvic surgery and complete tumor resection [17].

A fourth indication are *transgender* patients who undergo a genital reconstruction towards a feminine phenotype: male-to-female transgender (MTF) patients or transwomen.

According to the DSM-IV-R classification, transsexualism or gender identity disorder (GID) is an extreme form of gender dysphoria characterized by a strong and persistent identification with the opposite sex. It is accompanied by the wish to get rid of one's own primary and secondary sex characteristics and to live completely as someone from the opposite sex. In Belgium, the prevalence is around 7.75 male-to-female (MTF) and 2.96 female-to-male (FTM) per 100,000, which is similar to other Western European countries. The etiology of transsexualism remains unclear. Besides biological factors, such as hormonal abnormalities, morphology of sexual dimorphic brain nuclei, and genetic elements, psychological and sociocultural factors also seem to be important [19].

The Standards of Care (SOC) of the World Professional Association for Transgender Health (WPATH) describe the guidelines for transition from one gender to another in three stages: 1) living in the gender role consistent with gender identity; 2) the use of cross-sex hormone

therapy after living in the new gender role for at least 3 months; 3) gender-affirmation surgery after living in the new gender role and using hormonal therapy for at least 12 months [20].

It is worth taking a closer look at three important steps in the therapeutic process of male-to-female transgender individuals: hormones, surgery and screening.

Antiandrogen and estrogen therapy results in gynecomastia, reduced hair growth, redistribution of fat, and reduced testicular volume. All patients considering therapy should be screened for medical contraindications. After surgery, doses of estradiol 2–4 mg/d or conjugated equine estrogen 2.5 mg/d, are often sufficient to keep total testosterone levels to normal female levels of less than 25 ng/dL. Non-oral therapy can be offered as well. It is recommended that male-to-female transgender patients receiving estrogen therapy have an annual prolactin level assessment and visual field examination to screen for prolactinoma [20].

Surgery usually involves penile and testicular excision and the creation of a neovagina. Reported complications of surgery include vaginal and urethral stenosis, fistula formation, problems with remnants of erectile tissue, and pain. Vaginal dilation of the neovagina is required to maintain patency. Other surgical procedures that may be performed include breast implants and non-genital surgery, such as facial feminization surgery [20].

Sex reassignment surgery refers to genital procedures; namely vaginoplasty, clitoroplasty and labiaplasty. Gender reassignment surgery refers to the whole genital, facial and body procedures required to create a feminine appearance. The old definition of Edgerton (1974), stating that a sex change operation is in fact a ‘gender confirmation operation’, is currently being reintroduced by Monstrey (2013), with the intention of meaning that patients are not getting the gender ‘reassigned’ by such operations, but ‘confirmed’, as ‘gender’ is already there inside the patient himself/herself [21].

Surgical techniques to create a neovagina in male-to-female transsexuals may be classified into five categories: (1) application of nongenital skin grafts, (2) penile skin grafts, (3) penile-scrotal skin flaps, (4) nongenital skin flaps, and (5) pedicled intestinal transplants [22].

The inverted peno-scrotal flap is the technique of choice for vaginoplasty in male-to-female transsexuals; bowel segments are more and more used for secondary vaginoplasty, or even for primary vaginoplasty in patients following treatment to arrest puberty [21].

Age-appropriate screening for breast and prostate cancer is pertinent for male-to-female transgender patients. Opinions vary regarding the need for Pap testing in this population. In patients who have a neocervix created from the glans penis, routine cytologic examination of the neocervix may be indicated. The glans are more prone to cancerous changes than the skin of the penile shaft, and intraepithelial neoplasia of the glans is more likely to progress to invasive carcinoma than is intraepithelial neoplasia of other penile skin [20].

These four indications have a variable prevalence in the general population. Nevertheless, adequate vaginal reconstruction is of the utmost importance in all of them. The goals of vaginal reconstruction are as follows: to promote rapid wound healing, to decrease pelvic dead space, to restore the pelvic floor, and to re-establish normal sexual function and body image [23].

Probably the most important aspect with regard to reconstruction, especially in patients with MRKH, is the timing of the initial procedure. Ideally, the patient should be nearing the age for sexual intercourse, highly motivated, and emotionally mature. Patients who are relatively immature despite their chronological age are at great risk for poorer outcomes, which can lead to unfavorable healing. Failure of complete, unimpeded healing can result in the need for multiple revisionary procedures, the consequences of which may result in various degrees of sexual dysfunction. Thus, preoperative patient assessment and careful psychological preparation before any surgical intervention is crucial. Failure to do so will most probably influence the success of any surgical or nonsurgical intervention [24].

Functional vaginal reconstruction must accomplish several essential requirements: (a) adequate length of the vaginal wall, (b) sufficient transverse dimensions of the introitus and vaginal pouch, (c) healing without cicatricial contracture, and (d) the vaginal lining should be durable enough to withstand the forces associated with intercourse. All of these elements are essential to allow for adequate and pain-free intercourse [24].

Maintaining fertility is rare, for instance due to the mal-developed uterus that is usually associated with MRKH syndrome. However, in the rare cases in which the uterus and cervix are functional, they should be maintained during the reconstructive procedure to allow the potential for future childbearing. The ability to bear children remains possible in most cases due to the recent advances with in-vitro fertilization. Regardless of the presence or absence of a functional uterus, one must remember that the majority of patients with MRKH syndrome have functioning ovaries, which would therefore allow for such in-vitro procedures through

the use of a female surrogate. Regardless of the technique chosen, the surgeon must be experienced with the procedure and with its complications because the first attempt at reconstruction is the one with the highest likelihood of success [24].

Several techniques for non-surgical and surgical reconstruction of a vagina have been described in literature [1,25]

Non-surgical methods are based on dilation. The first successful technique was described by Frank in 1938 [26]. It involves the use of vaginal molds, initially made from pyrex and currently made from plastic, of increasing width and length. The patient is asked to apply gentle pressure on the vaginal dimple for at least 30 minutes daily for several months with the aim to achieve a vaginal length of 7-8 cm. This therapy works by the pressure effect which acts to progressively stretch the vagina with time. The prerequisite for this treatment is first a healthy non-scarred vaginal dimple which is amenable to stretching and second, but more important, a motivated patient who is ready to adhere to such a lengthy treatment [25].

Frank's method was an inspiration for many others, such as Ingram, who used these principles in 1981 to create a bicycle seat stool [27].

These conservative methods are praised for their simplicity and low morbidity [28]. However, they can be associated with rare, but potentially severe complications such as vaginal apex necrosis [29]. They also have a mental and physical impact on the patient that should be taken into consideration [2].

Over the years multiple surgical methods with different materials have been developed, each with their own advantages and disadvantages [2]. More than 20 surgical approaches have been proposed so far [30].

The surgical techniques for vaginoplasty can be considered on the so-called 'reconstructive ladder', going from simple to much more complex reconstructive techniques. [2].

The oldest technique, that is still used to this day, is the *McIndoe technique* where a neovaginal space is dissected between the bladder and rectum, then lined with different types of tissue. This technique dates back from 1950 and uses a split thickness skin graft (STG) or a full thickness skin graft (FTG) [31]. These grafts can be harvested in the lower abdomen, the groin or the gluteal region. It has the advantage that it is a rather straightforward surgical

technique. The disadvantages are scarring of the donor region and stenosis of the neovagina as a result of contracture, especially with STG. Persistent postoperative dilation is necessary [2].

The next step on the reconstructive ladder is the use of *myocutaneous flaps*. Here, the muscle and its underlying skin appendage, which is vascularised by perforating vessels, is transplanted into the defect. Flaps from the M. Gracilis en de M. Rectus Abdominis are used frequently [32,33]. This technique is preserved for major traumata where colpectomy has been performed: myocutaneous flaps are rather thick and can fill up the dead space that remains after colpectomy or after more elaborate oncologic resections [2]. These muscle flaps require the sacrifice of functioning muscle. Particular disadvantages of the rectus flaps are the significant complications with abdominal wall bulging and hernias [34].

Over the past decades, there has been a clear shift from myocutaneous flaps to *perforator flaps*, to reduce the morbidity associated with muscle harvest. Perforator flaps are adipocutaneous or fasciocutaneous flaps based on vessels that directly supply an area of skin and subcutaneous fat and run either through a muscle (musculocutaneous perforator) or through the intermuscular septum (septocutaneous perforator). Careful dissection of the perforator vessel down to the deeper structures will result in a sufficiently long pedicle which will then allow for advancement, transposition or rotation of the fasciocutaneous island. In the gluteal area, inferior (IGAP) and superior (SGAP) gluteal artery perforator flap are based on perforators arising from inferior and superior gluteal artery, respectively. These flaps have been popularised for breast reconstruction as a microsurgical transfer and also widely used as advancement or transposition flaps for lumbosacral defects. They avoid the need to harvest the gluteus maximus muscle. Similarly, these flaps are used for reconstruction of the posterior vaginal wall in an immediate or delayed setting, resulting in good functional outcomes with low donor-site morbidity [35].

Recently, the *propeller flap* has been described as a fasciocutaneous island flap that could be rotated around the pedicle forming the axis of the 'propeller'. This new type of local flap allows for reconstruction of a defect directly adjacent to a dissected perforator vessel, which acts as a pivot point and supplies the fasciocutaneous island. Initially popularised for lower limb reconstruction, the propeller flap concept has been applied to resurface pressure sores [35].

The *Pudendal-Thigh Flap technique*, first described in 1989, uses two thin fasciocutaneous flaps from the region just lateral to the hair bearing area of the labia majora. It is the most

popular technique for patients with MRKH syndrome. One of the few disadvantages of this technique is that a persistent postoperative epilation is necessary to prevent hair growth in the neovagina [2,36]. Recently, a variation of this technique that uses pudendal thigh flaps thinned with liposuction has been described [37].

The last two options for vagina reconstruction that will be discussed are of a more invasive nature.

The *laparoscopic* methods include the Vecchietti procedure and Davydov procedures. Laparoscopic techniques have the advantage of less bleeding, adhesion formation, and post-operative pain in addition to shorter hospital stay, faster recovery, and better cosmetic outcome. Initially described in 1965 as an open operation, the Vecchietti procedure is now usually performed laparoscopically [38]. An acrylic olive is attached to the vaginal dimple. This olive is connected with threads, who pass through the vagina to a traction device. This way, there is a continuous progressive pressure. As with the Vecchietti procedure, the Davydov procedure was initially described as an open procedure. It was then modified to a laparoscopic approach which is more commonly used today although the former is still used in some countries. This method consists of a three-stage operation involving dissection of the rectovesical space with abdominal mobilization of the peritoneum, attachment of the peritoneum to the created introitus, and finally closure of the neovaginal vault with purse-string suture. After the operation patients are instructed either to keep a mold in the vagina or to perform regular vaginal dilation to avoid vaginal collapse before the complete epithelialization has occurred. Unlike the Vecchietti procedure, the Davydov technique can be used in patients who have genital scarring due to previous perineal surgery because it does not require the vaginal skin to be elastic [25].

Intestinal vaginoplasty is a technique that uses interposition of *isolated bowel segments*. This was first described by Baldwin in 1904 when he used a segment of the small bowel to create a neovagina [39]. However, due to the high mortality and morbidity rates, this procedure was abandoned and was only revisited in the early 1970s. The procedure involves the isolation of a segment of the bowel, usually 10-12 cm in length, along with its vascular pedicle which is then transposed to the perineum at the level where the vagina should be.

Available options here are jejunum, ileum, caecum and sigmoid colon. The main advantage here is that these tissues have a layer of mucosa, which acts as a natural lubrication of the vagina and thus facilitates sexual intercourse. The disadvantages are that these patients have

to undergo intra-abdominal surgery that could result in postoperative complications. Other disadvantages are excessive mucus production, an increased risk of coital bleeding and an increased risk of neovaginal stenosis that could require permanent dilation [2].

This literature review will focus on the latter technique and will try to answer the question which should be the bowel segment of choice.

METHODS

Search strategy

A search strategy was developed to identify publications on intestinal vaginoplasty. Articles were collected by several methods:

- A search of the published literature was conducted using the databases MEDLINE, Web of Science and Cochrane Library. Medical Subject Headings (MeSH) were used in the MEDLINE database. Combinations of the following keywords were used: “vaginoplasty”, “vagina reconstruction”, “neovagina”, “jejunum”, “ileum”, “caecum”, “colon”, “sigmoid”, “intestine”, “bowel”, “small”, “large”.
- The evidence-based clinical resource UpToDate was searched for medical information.
- The library of the Faculty of Medicine and Health Sciences from the Ghent University was consulted.
- Multiple articles were provided by the promotor of this literature review, Prof. Dr. Stan Monstrey.

After running these methods, 85 potentially relevant articles were identified. All titles and abstracts were screened for eligibility, followed by a full text analysis of potentially relevant abstracts.

Literature selection

Inclusion criteria

To be included, the following criteria had to be met:

- Articles that provide information on small or large bowel segment vaginoplasty (jejunum, ileum, caecum, sigmoid).
- Articles written or translated in English, French and Dutch.
- Articles published between July 2004 and July 2014.
- The indications for vaginoplasty are those as described in the introduction.
- An average follow-up period of at least one year.
- A minimum of three patients included in the study.

Exclusion criteria

Exclusion criteria were as follows:

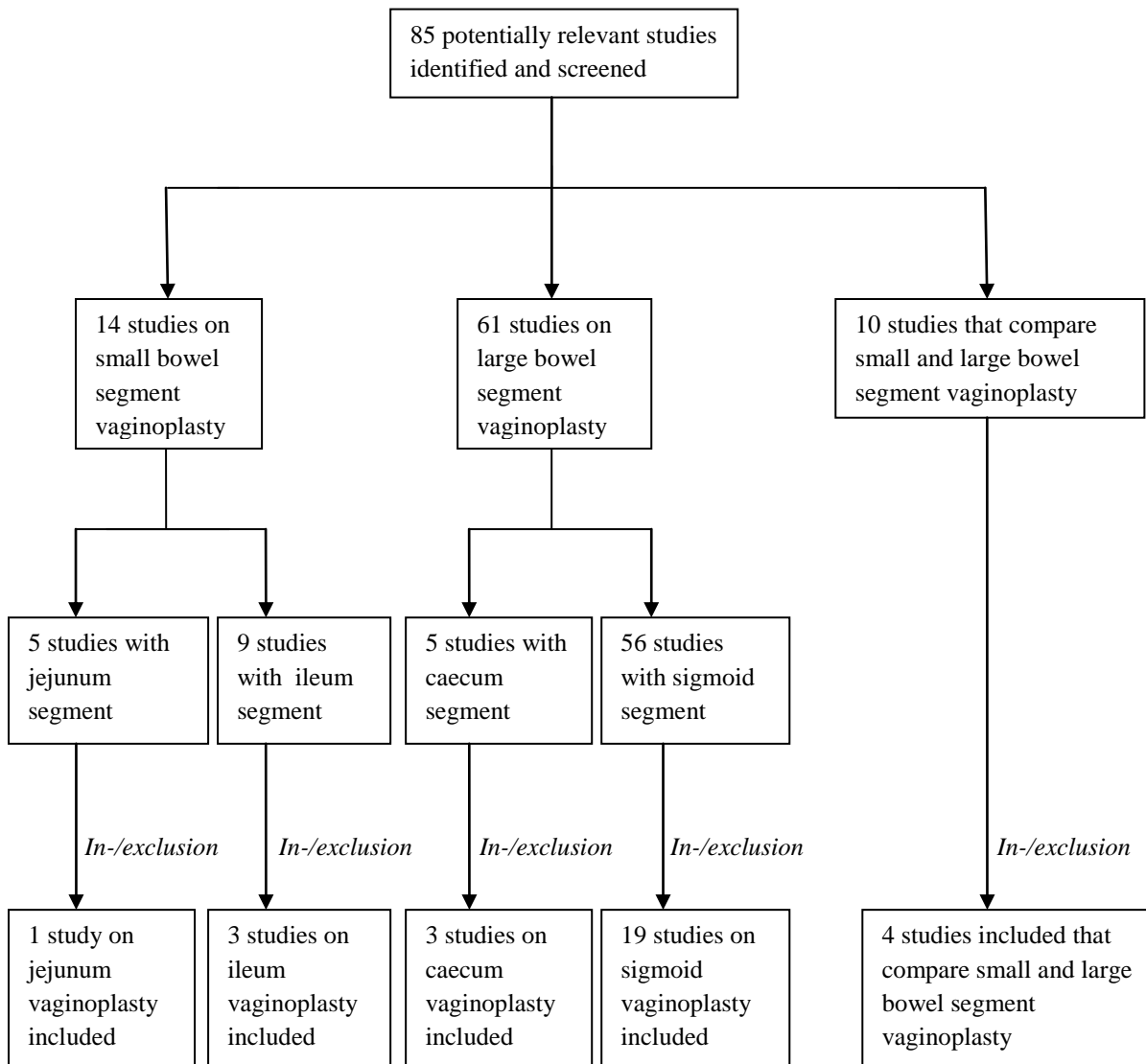
- Articles in which the results from different techniques could not clearly be distinguished.
- Articles of inferior quality, as determined by the SQUIRE (Standards for Quality Improvement Reporting Excellence) guidelines.
- When an author published multiple articles in different journals, possible overlap of the same patients was taken into account. The article with the highest patient population was then used for this literature review.
- When different authors used patients from an equal hospital for their studies, possible overlap of the same patients was taken into account. The article with the highest patient population was then used for this literature review.

After inclusion and exclusion, 30 articles were taken into consideration for this literature review (Figure 1).

Data extraction and analysis

From these 30 publications, information was gathered on patients, study design, indications, patient age, surgical procedure, anatomical results, functional results, acute complications and long-term complications.

Figure 1: Flowchart of literature selection



RESULTS

Patients

The selected 30 articles provided information on a total amount of 917 patients (Table 1). These 917 patients were treated with intestinal vaginoplasty. Jejunum vaginoplasty was performed on 34 patients (3.7%), ileum vaginoplasty on 202 patients (22.0%), caecum vaginoplasty on 33 patients (3.6%) and sigmoid vaginoplasty on 648 patients (70.7%) (Table 2).

Table 1: Summary of studies (1)

<u>Study</u>	<u>Bowel segment</u>	<u>Patients</u>
1. Erman Akar M et al. 2013	Jejunum	34
2. Trombetta C et al. 2005	Ileum	6
3. Wu JX et al. 2009	Ileum	86
4. Zhao YZ et al. 2011	Ileum	82
5. Abd El-Aziz S et al. 2006	Caecum	11
6. Bridoux V et al. 2010	Caecum	8
7. Khulpateea BR et al. 2014	Caecum	14
8. Abudaia J et al. 2005	Sigmoid	5
9. Cai B et al. 2007	Sigmoid	26
10. Cao L et al. 2012	Sigmoid	14
11. Carrard C et al. 2012	Sigmoid	48
12. Djordjevic ML et al. 2011	Sigmoid	86
13. Ekinici S et al. 2006	Sigmoid	6
14. Fahmy MAB et al. 2011	Sigmoid	15
15. Fotopoulou C et al. 2008	Sigmoid	7
16. Garcia-Roig M et al. 2013	Sigmoid	6
17. Imperato E et al. 2007	Sigmoid	62
18. Kapoor R et al. 2006	Sigmoid	14
19. Khen-Dunlop N et al. 2007	Sigmoid	23
20. Kim SK et al. 2011	Sigmoid	12
21. Li S et al. 2014	Sigmoid	15
22. Nowier A et al. 2012	Sigmoid	31

23. Rawat J et al. 2010	Sigmoid	8
24. Shen Y et al. 2009	Sigmoid	11
25. Yin D et al. 2013	Sigmoid	5
26. Zhong CX et al. 2012	Sigmoid	150
27. Burgu B et al. 2007	Ileum	14
	Sigmoid	7
28. Karateke A et al. 2010	Ileum	2
	Sigmoid	27
29. Lima M et al. 2010	Ileum	1
	Sigmoid	46
30. Wright C et al. 2014	Ileum	11
	Sigmoid	24

		917

Table 2: Summary of studies (2)

<u>Bowel segment</u>	<u>Studies</u>	<u>Patients</u>
Jejunum	1	34
Ileum	7	202
Caecum	3	33
Sigmoid	23	648

Study design

This literature review aimed to include both prospective and retrospective studies. Four prospective studies that matched the selection criteria were identified [17,44,49,50]. The other 26 studies were of a retrospective nature.

Indications

The indications that were encountered in the literature were distributed into the four major categories, as described in the introduction. Table 3 shows a detailed list of the used bowel segment per indication and their corresponding patients.

Congenital vaginal agenesis (which included primarily Mayer-Rokitansky-Küster-Hauser syndrome but also isolated vaginal agenesis, cloacal exstrophy, bladder exstrophy and urogenital sinus anomaly) contributed 684 patients (74.6 %). Of this group, 31 patients underwent jejunum vaginoplasty, 128 patients underwent ileum vaginoplasty and 525 patients underwent sigmoid vaginoplasty.

Disorders of sex development (which included congenital conditions of the reproductive system such as congenital adrenal hyperplasia and androgen insensitivity syndrome) contributed 94 patients (10.3%). Of this group, 2 patients underwent jejunum vaginoplasty, 23 patients underwent ileum vaginoplasty and 69 patients underwent sigmoid vaginoplasty.

History of colpectomy (which included previous pelvic oncologic surgery or radiotherapy and genital trauma) contributed 58 patients (6.3%). Of this group, 1 patient underwent jejunum vaginoplasty, 3 patients underwent ileum vaginoplasty, 33 patients underwent caecum vaginoplasty and 21 patients underwent sigmoid vaginoplasty.

Male-to-female transgender contributed 81 patients (8.8%). Of this group, 48 patients underwent ileum vaginoplasty and 33 patients underwent sigmoid vaginoplasty.

Table 3: Indications – Bowel Segment

	<u>Jejunum</u>	<u>Ileum</u>	<u>Caecum</u>	<u>Sigmoid</u>
Congenital vaginal agenesis	31	128		525
Disorders of sex development	2	23		69
History of colpectomy	1	3	33	21
MTF transgender		48		33

Patient age

For patients who underwent jejunum vaginoplasty, age ranged from 16 to 31 years with a mean age of 24.5 years [40]. For patients who underwent ileum vaginoplasty, age ranged from 1 to 47 years with a mean age of 24.8 years [41-43,68]. For patients who underwent caecum vaginoplasty, age ranged from 29 to 57 years with a mean age of 42 years [44,45]. For patients who underwent sigmoid vaginoplasty, age ranged from 1 to 61 years with a mean age of 20.1 years [17,47-62,64,67,68].

Surgical procedure

Preoperative workout

Preoperative workout of the patient could include clinical examination, chromosomal analysis, hormonal assay, transvaginal/transabdominal ultrasound, abdominal/pelvic CT, abdominal/pelvic MRI, abdominal/pelvic/chest x-ray, intravenous pyelography, retrograde urethrography, voiding cystourethrography, laparoscopic evaluation, colposcopy, colonoscopy and psychological assessment.

The patient was treated by a team of physicians that could include a gynecologist, urologist, pediatric surgeon, plastic surgeon, gastrointestinal surgeon, endocrinologist, geneticist, radiologist and psychologist [17,47,48,51-53,55-66].

Preoperative management

Start of the preoperative management ranged from three days before the operation to the night before the operation [17,40,43,44,48,52,53,55,60,64,66] and included mechanical bowel preparation under the form of laxatives and enemata [17,41-44,48,51-53,55,58-60,64,66,68], low-residue semifluid and/or liquid diet [42,43,48,52,59,64], fasting [40,48,64], oral or intravenous antibiotics [42,48,51-53,55,58-60,64,68] and prophylactic administration of heparin [41].

Surgical technique abdomen

Patients were generally placed in the lithotomy position, in order to achieve a good intra-abdominal exposure as well as wide access to the perineum and the introitus [40-42,47,49,51,52,56,58-60,62-64,66]. Other positions were the Lloyd-Davies position [48] and a special position with the left leg in the lithotomy position and the right leg in the Lloyd-Davis position, to provide unlimited access to the neovagina cavity and anal canal while, at the same time, avoiding interference with the insertion and handling of the laparoscopic instruments [43].

After induction of general anesthesia [40,41,43,56,58,60,61,64,66] and/or epidural anesthesia [56,60,62,63] the surgery was ready to start.

The bowel segment could be harvested by *laparoscopy* [42,43,48-50,58,59,62,64] or by *laparotomy* through a midline incision [17,40,41,60,61,66], a left paramedian incision [52], a Pfannenstiel incision [41,47,49-51,53,55-57,61] and a Maylard incision [66].

In the majority of cases the surgeon opted for straight intestinal segments. However, different folding techniques to create a larger diameter of the tube have also been described, such as the *detubularization and retubularization* technique [40,41,54] and the *pouch* technique [65,68]. To test the adequacy of the diameter of the intestinal transplant, two fingers could be inserted into its lumen [40].

The length of the intestinal segment varied considerably. The mean length of jejunum segments was 30 cm [40]. Ileum segments ranged from 12 cm to 20 cm with a mean length of 17.2 cm [41,42]. The mean length of caecum segments was 15 cm [45,46]. Sigmoid segments ranged from 7.5 cm to 20 cm with a mean length of 13.9 cm [17,47,48,51-57,59-62,64,66].

Several techniques for identifying the vascular pedicle that provides blood flow to the transplant were described, including the use of an ultrasonically powered instrument [43], temporarily clamping the artery to test the vascular tenacity [46,48,52,66] and the transillumination technique [17,41,45,52,55,66].

Different vascular pedicles were used depending on the transplant, including the first jejunal artery for jejunum segments [40], the ileocolic artery or the right colic artery for caecum segments [44-46] and the sigmoid arteries or the superior rectal arteries for sigmoid segments [17,47,48,51-53,55,57,59,61,64].

Intra-operative wash of the intestinal segment could be performed with a povidone-iodine solution [44,45].

The intestinal phase was concluded by restoration of the gastrointestinal continuity by a single- or double-layered end-to-end anastomosis. Depending on the surgeon this was performed hand-sewn or with a circular stapler [40-44,46-49,51-53,55,56,58-64,66]. Potential air leakage could be detected by transanal insufflation of air [58].

[Surgical technique perineum](#)

The perineal phase commenced with an X-shaped [43,47], U-shaped [48,50,51,59], H-shaped [55,56] or Y-shaped [58] incision, depending on the surgeon's preference.

A neovaginal cavity was created dorsal to the urethra and bladder and ventral to the rectum. This was achieved by blunt dissection [40-42,47,48,52,58,59,63,64,66], sharp dissection [40,53,55] or with Hegar sounds dilation [56,60].

In this manner, a two-finger- [42,43,47,49,56,66] or three-finger-wide space [62,64] was established.

One must take care not to create too large a cleavage, which could predispose to vaginal prolapse [57].

The proximal end of the isolated jejunum, ileum and sigmoid segments was closed in two layers using absorbable or non-absorbable sutures. The isolated caecum segments were rotated counter-clockwise 180° and the appendix was removed. The created proximal ending of the neovagina was then fixated to the sacral promontory, the posterior wall of the pelvic cavity, the retropubic periosteum, the remnants of the Mullerian ducts, the uterosacral ligaments or the round ligament and the broad ligament of the uterus to prevent prolapse [17,40,42-47,50-53,55-57,59-61,64,66].

The distal end of the isolated bowel segments was approximated to the introitus to create an anastomosis with the perineum using skin and mucosal flaps [17,40-48,51-53,55-57,60-64,66].

The lateral portions of the neovagina could be fixated to the levator ani muscles to prevent prolapse as well [53,55].

Depending on the indication of the surgery, additional procedures were performed.

When the patient had a history of colpectomy, a pedicled, tension free, greater omental flap was placed in the pelvic dead space to fill the pelvic cavity and thus prevent the small bowel from dropping into the denuded area which could cause complications such as intestinal obstruction and fistula formation [45]. If any vaginal tissue was present, a completion-vaginectomy was performed to resect the vagina including the labia minora prior to proceeding to the vaginal reconstruction procedure [46,63]. A type III radical hysterectomy could also be performed in these patients [63].

In male-to-female transgender patients and patients with androgen insensitivity syndrome, gonadectomy, clitoroplasty, vulvoplasty, urethroplasty and perineoplasty could be performed [43,60].

Postoperative management

Postoperative management varied considerably between studies and could include several of the following methods:

- Gauzes were placed in the neovagina for 1 - 10 days, to facilitate graft adhesion to the surrounding tissue [43,44,48,52,53,55,56,61,63].
- The patient was put in frog-leg position for 3 - 4 days [58].
- A Penrose drain was placed in the neovagina and removed after 3 - 10 days [17,43,48,58,68].
- A vaginal stent, with or without Estradiol-cream, was placed in the neovagina for 2 - 7 days [17,48,54,58-60,64].
- Sanitary pads were placed in the neovagina, to absorb intestinal discharge [43,46].
- Oral or intravenous antibiotics were administered to prevent urinary tract infection [42,43,48,51,52,55,59,64].
- A Foley urethral catheter was placed and removed after 2 - 10 days [41,43,48,49,51-56,58,61,64].
- The patient was encouraged to use a vaginal dilator daily for 1 – 24 weeks [41-43,46,47,50,51,56,57,60,64]
- Doppler ultrasonography of the anastomosed vessels was performed twice per day to monitor the flap for the first 5 days postoperatively [40].
- The flap was monitored daily from the vaginal introitus with the occasional use of needle puncture and observation of tissue color [40,42,43].
- The patient was advised to wash the neovagina daily [41-43,47,48,51-53,55,56,59-61,68].
- The patient was instructed to fast for a few days [48,59,64].
- The patient was put on a low-residue semifluid and/or liquid diet [48,64].
- Parenteral nutrition was given to the patient before functional recovery of the intestinal tract [42,43,54].

Operation statistics and follow-up

Operating time varied considerably among the different bowel segments. Mean operating time for jejunum segments was 300 minutes, ranging from 240 to 480 minutes [40]. Mean operating time for ileum segments was 180 minutes, ranging from 158 to 255 minutes [41-43]. Mean operating time for caecum segments was 65 minutes, ranging from 45 to 100 minutes [45]. Mean operating time for sigmoid segments was 179.6 minutes, ranging from 60 to 840 minutes [17,48-50,53-55,57-60,62,63].

Blood loss was poorly reported. The mean blood loss among all the bowel segments was 227.3 ml, ranging from 100 to 600 ml [43,49,63].

Two studies reported that patients could start mobilizing on the second postoperative day [41,42].

The mean hospital stay was well reported. Patients who underwent jejunum vaginoplasty were discharged 14 days after the operation, ranging from 12 to 20 days [40]. Patients who underwent ileum vaginoplasty were discharged 13.6 days after the operation, ranging from 7 to 16 days [41-43]. Patients who underwent caecum vaginoplasty were discharged 30 days after the operation, ranging from 20 to 45 days [45]. Patients who underwent sigmoid vaginoplasty were discharged 8.5 days after the operation, ranging from 5 to 27 days [17,48,49,51-55,58-60,62].

The mean length of follow-up was well reported. Patients who underwent jejunum vaginoplasty were followed for 50 months on average, ranging from 20 to 87 months [40]. Patients who underwent ileum vaginoplasty were followed for 29.6 months on average, ranging from 3 to 90 months [41-43,68]. Patients who underwent caecum vaginoplasty were followed for 37 months on average [46]. Patients who underwent sigmoid vaginoplasty were followed for 45.7 months on average, ranging from 3 to 288 months [17,47-49,51-57,59-61,63,64,68].

Anatomical results

The mean length and width of the neovagina for jejunum grafts were respectively 9.8 cm, ranging from 7 to 12 cm; and 3.1 cm, ranging from 2.6 to 3.8 cm [40].

The mean length and width of the neovagina for ileum grafts were respectively 15.7 cm, ranging from 10.5 to 18 cm; and 3.3 cm, ranging from 2.5 to 4.5 cm [41-43].

The mean length and width of the neovagina for caecum grafts were not reported.

The mean length and width of the neovagina for sigmoid grafts were respectively 12.3 cm, ranging from 2 to 16 cm; and 3.6 cm, ranging from 0.5 to 4 cm [17,48,49,51,55,58-60,62-64].

The pH of the neovagina was only reported in one study. In this study, the mean pH of the sigmoid neovagina was 6, which is a slightly lower acidity than in a normal vagina [58].

Functional results

Functional results were poorly described and included the time between the operation and the first sexual intercourse, sexual health, sexual activity, sexual satisfaction and dyspareunia.

The time between the operation and the first sexual intercourse was reported in 3 studies on ileum vaginoplasty with a mean interval of 5.1 months, ranging from 2 to 12 months [41-43], and in 5 studies on sigmoid vaginoplasty with a mean interval of 5.9 months, ranging from 1 to 48 months [17,50,51,55,59].

To report sexual health, a few studies used the Female Sexual Function Index (FSFI). One study on jejunum vaginoplasty reported a mean total score of 27.5, ranging from 19.5 to 33.2 [40]. Five studies on sigmoid vaginoplasty reported a mean total score of 27.6, ranging from 11.5 to 35.7 [17,49-51,63].

Sexual activity and sexual satisfaction were poorly reported. It was also difficult to compare between studies because of pediatric patient populations, adult patient populations and mixed patient populations. Generally, it can be said that most patients who had a partner were sexually active and described it as satisfactory [17,40-51,55-60,62-64,67,68].

Persistent dyspareunia was reported in 5 studies and affected 17 of the 154 patients (11.0%) [17,48,55,57,67].

Acute complications

Intraoperative complications

Jejunum

In 1 study with a total of 34 patients, no intraoperative complications were reported.

Ileum

In 7 studies with a total of 202 patients, 3 cases of intraoperative complications were reported (1.5%). All 3 were injuries to the rectum and/or bladder, that were repaired immediately [43]. Table 4 shows an overview of the intraoperative complications of ileum vaginoplasty.

Table 4: Intraoperative Complications Ileum

<u>Severity</u>	<u>#</u>	<u>Complication</u>	<u>Percentage</u>
Mild	3	Injury to the rectum and/or bladder	1.5%

Caecum

In 3 studies with a total of 33 patients, no intraoperative complications were reported.

Sigmoid

In 23 studies with a total of 648 patients, 4 cases of intraoperative complications were reported (0.6%). Three were rectal injuries that were immediately detected and sutured (0.5%) [50,66]. One was blood loss during the perineal canalization that required blood transfusion (0.2%) [48]. Table 5 shows an overview of the intraoperative complications of sigmoid vaginoplasty.

Table 5: Intraoperative Complications Sigmoid

<u>Severity</u>	<u>#</u>	<u>Complication</u>	<u>Percentage</u>
Mild	3	Rectal injury	0.6%
	1	Blood loss during perineal canalization that required blood transfusion	

Postoperative complications

Jejunum

In 1 study with a total of 34 patients, 3 cases of postoperative complications were reported (8.8%). All 3 were venous compromise, that were treated with venous reanastomosis [40]. Table 6 shows an overview of the postoperative complications of jejunum vaginoplasty.

Table 6: Postoperative Complications Jejunum

Severity	#	Complication	Percentage
Moderate	3	Venous compromise	8.8%

Ileum

In 7 studies with a total of 202 patients, 17 cases of postoperative complications were reported (8.4%). Four were ileus that were treated conservatively or surgically (2.0%) [42,43]. Three were a delayed healing of the ileocutaneous anastomosis that were treated with serial debridement and dress changing (1.5%) [43]. Three were a perineal rash, induced by neovaginal discharge, that disappeared after irrigation of the neovagina with acidic feminine liquid (1.5%) [43]. Two were urethra-vaginal fistula (1.0%) [43,65]. One was a urinary tract infection (0.5%) [41]. One was an intra-abdominal hemorrhage, that was treated conservatively (0.5%) [42]. One was a urethral meatal stenosis, that was relieved with catheter drainage (0.5%) [42]. One was acute renal failure after self-medication with traditional Chinese medicinal herbs that was treated with 1 week of hormone therapy, blood transfusion, and continuous renal replacement therapy (0.5%) [43]. One was ileal necrosis, that was treated with an ileostomy (0.5%) [66]. Table 7 shows an overview of the postoperative complications of ileum vaginoplasty.

Table 7: Postoperative Complications Ileum

Severity	#	Complication	Percentage
Mild	4	Ileus	6.5%
	3	Delayed healing of the ileocutaneous anastomosis	
	3	Perineal rash	
	1	Urinary tract infection	
	1	Intra-abdominal hemorrhage	
	1	Urethral meatal stenosis	
	1	Urethra-vaginal fistula	
Moderate	2	Urethra-vaginal fistula	1.5%
	1	Acute renal failure	
Severe	1	Ileal necrosis	0.5%

Caecum

In 3 studies with a total of 33 patients, 6 cases of postoperative complications were reported (18.2%). Three were ileus that were treated conservatively (9.1%) [45]. Two were a wound infection that were treated with drainage and/or antibiotic therapy (6.1%) [44,45]. One was a post-operative hemorrhage that was treated with ligation of the bleeding pelvic vessel (3.0%) [45]. Table 8 shows an overview of the postoperative complications of caecum vaginoplasty.

Table 8: Postoperative Complications Caecum

Severity	#	Complication	Percentage
Mild	3	Ileus	18.2%
	2	Wound infection	
	1	Post-operative hemorrhage	

Sigmoid

In 23 studies with a total of 648 patients, 45 cases of postoperative complications were reported (6.9%). Ten were ileus that were treated conservatively or surgically (1.5%) [55,56,61,64,67,68]. Nine were a wound infection (1.4%) [53,56,57,59,61,63,66]. Five were pelvic hematoma that were treated with surgical re-exploration and hemostasis (0.8%) [50,55,57]. Three were a urinary tract infection (0.5%) [48,57]. Three were urinary incontinence (0.5%) [57]. Two were an incision abscess, of which one required drainage (0.3%) [48]. One was intestinal leakage that was treated with fasting, gastro-intestinal decompression and intravenous nutrition (0.2%) [49]. One was urinary retention that was relieved with reinsertion of a catheter (0.2%) [49]. One was hydronephrosis that was relieved with placement of a double-J tube in the affected ureter (0.2%) [49]. One was wound dehiscence that required reoperation (0.2%) [17]. One was an abdominal empyema that was treated with surgical drainage (0.2%) [17]. One was necrotizing fasciitis and leakage from the bowel anastomosis that was treated with antibiotics, surgical debridement and a proximal diverting colostomy (0.2%) [55]. One was compartment syndrome that was treated with surgical decompression (0.2%) [57]. One was a stress ulcer (0.2%) [59]. One was an acute abdomen, secondary to vaginal rupture, that was treated with laparotomy (0.2%) [60]. One was a colorectal fistula that was treated with a transverse colostomy (0.2%) [64]. One was necrosis of the sigmoid conduit that required exeresis (0.2%) [67]. One was a pelvic abscess that was treated with surgical drainage (0.2%) [67]. One patient died because of renal failure

and sepsis that led to multiple organ failure (0.2%) [52]. Table 9 shows an overview of the postoperative complications of sigmoid vaginoplasty.

Table 9: Postoperative Complications Sigmoid

<u>Severity</u>	<u>#</u>	<u>Complication</u>	<u>Percentage</u>
Mild	10	Ileus	5.1%
	9	Wound infection	
	5	Pelvic hematoma	
	3	Urinary tract infection	
	3	Urinary incontinence	
	1	Urinary retention	
	1	Wound dehiscence	
	Moderate	2	
1		Pelvic abscess	
1		Abdominal empyema	
1		Stress ulcer	
1		Colorectal fistula	
1		Intestinal leakage	
1		Hydronephrosis	
Severe	1	Death	1.0%
	1	Compartment syndrome	
	1	Acute abdomen	
	1	Necrotizing fasciitis and leakage from the bowel anastomosis	
	1	Necrosis of the sigmoid conduit	

Long-term complications

Jejunum

In 1 study with a total of 34 patients, 2 cases of long-term complications were reported (5.9%). Most patients had a transient vaginal discharge which the patient found initially embarrassing but decreased 3 - 6 months postoperatively and was not a source of concern [40]. One was vaginal stenosis following botulinum toxin therapy that was treated with dilation (2.9%) [40]. One was prolapse of the neovagina that was treated with surgical

resection (2.9%) [40]. Table 10 shows an overview of the long-term complications of jejunum vaginoplasty.

Table 10: Long-term Complications Jejunum

Severity	#	Complication	Percentage
Mild	1	Stenosis of the neovagina	5.9%
	1	Prolapse of the neovagina	

Ileum

In 7 studies with a total of 202 patients, 12 cases of long-term complications were described (5.9%) Most patients had a transient vaginal discharge which the patient found initially embarrassing but decreased 3 - 6 months postoperatively and was not a source of concern [41-43,65,66,68]. Eleven were stenosis of the neovagina that were treated with dilation or scar resection and local skin flap transfer (5.4%) [42,43,65,68]. One case was prolapse of the neovagina (0.5%) [65]. Table 11 shows an overview of the long-term complications of ileum vaginoplasty.

Table 11: Long-term Complications Ileum

Severity	#	Complication	Percentage
Mild	11	Stenosis of the neovagina	5.9%
	1	Prolapse of the neovagina	

Caecum

In 3 studies with a total of 33 patients, three cases of long-term complications were reported (9.1%). Most patients had a transient vaginal discharge which the patient found initially embarrassing but decreased 3 - 6 months postoperatively and was not a source of concern [44,46]. Two were stenosis of the neovagina that were treated with dilation (6.1%) [45]. One was persistent postcoital spotting (3.0%) [46]. Table 12 shows an overview of the long-term complications of caecum vaginoplasty.

Table 12: Long-term Complications Caecum

Severity	#	Complication	Percentage
Mild	2	Stenosis of the neovagina	9.1%
	1	Persistent postcoital spotting	

Sigmoid

In 23 studies with a total of 648 patients, 90 cases of long-term complications were reported (13.9%). Most patients had a transient vaginal discharge which the patient found initially embarrassing but decreased 3 - 6 months postoperatively and was not a source of concern [17,47-49,51,53,57,58,60,62,64-66,68]. Fifty-seven were stenosis of the neovagina and were treated with dilation or reconstruction (Y-V-or Z-plasty) (8.8%) [17,47,48,51,53,55,60,68]. Twenty were prolapse of the neovagina that were treated with vaginal resection of the prolapsed tissue and/or surgical repair (3.1%) [17,50,51,55,61]. Eight were a malodor of the neovagina (1.2%) [17,49,60]. One was a persistent vaginal discharge (0.2%) [17]. One was a left tubal abscess 2 years after surgery that was drained by laparoscopy and the left tube was removed (0.2%) [50]. One was an incisional hernia that was treated with abdominal wall hernioplasty (0.2%) [17]. One was a diversion colitis (0.2%) [65]. One was an ulcerative colitis that was treated with a total colectomy while the neovagina was treated topically (0.2%) [67]. Table 13 shows an overview of the long-term complications of sigmoid vaginoplasty.

Table 13: Long-term Complications Sigmoid

Severity	#	Complication	Percentage
Mild	57	Stenosis of the neovagina	13.3%
	20	Prolapse of the neovagina	
	8	Malodor of the neovagina	
	1	Persistent vaginal discharge	
Moderate	1	Left tubal abscess	0.4%
	1	Incisional hernia	
Severe	1	Diversion colitis	0.4%
	1	Ulcerative colitis	

DISCUSSION

An analysis of the literature on intestinal vaginoplasty with jejunum, ileum, caecum and sigmoid segments was conducted. Results on patients, study design, indications, patient age, surgical procedure, anatomical parameters, functional parameters, acute complications and long-term complications were evaluated.

It is important to emphasize that there is a significant difference in the available literature on the different bowel segments. While many qualitative studies on sigmoid vaginoplasty are published, only a few qualitative studies on jejunum, ileum and caecum vaginoplasty are available. This should be taken into account when comparing results from different intestinal transplants.

There is no distinct reason for why the majority of intestinal vaginoplasties are performed with sigmoid conduits. One explanation might be that sigmoid transplants are more commonly used by gynecologists and plastic surgeons, while urologists prefer ileum transplants because of their background with its use in the orthotopic neobladder reconstruction.

This literature review aimed to include both prospective and retrospective studies. Only a few prospective studies that matched the selection criteria were identified.

The most common indication for intestinal vaginoplasty was congenital vaginal agenesis (74.6%) followed by disorders of sex development (10.3%), male-to-female transgender (8.8%) and history of colectomy (6.3%). The sigmoid segment was the preferred intestinal transplant in patients with congenital vaginal agenesis and patients with disorders of sex-development. The ileum segment was the preferred intestinal transplant in male-to-female transgender patients. The caecum segment was the preferred intestinal transplant in patients with a history of colectomy.

The mean age for patients undergoing jejunum, ileum and sigmoid vaginoplasty was comparable (respectively 24.5, 24.8 and 20.1 years). The mean age for caecum vaginoplasty was higher (42 years), which relates to the fact that this segment was only used in patients with a history of colectomy, a procedure that is more commonly performed in elder patients.

The mean operating time varied considerably among the different bowel segments (300 minutes for jejunum vaginoplasty, 180 minutes for ileum and sigmoid vaginoplasty and 65 minutes for caecum vaginoplasty).

The mean hospital stay for patients undergoing jejunum, ileum and sigmoid vaginoplasty was comparable (respectively 14 days, 13.6 days and 8.5 days). The mean hospital stay for patients undergoing caecum vaginoplasty was longer (30 days), which relates to the fact that this segment was only used in patients with a history of colpectomy who consequently had to recover from a major operation.

The mean length of follow-up was adequate for every bowel segment (50 months for jejunum vaginoplasty, 29.6 months for ileum vaginoplasty, 37 months for caecum vaginoplasty and 45.7 months for sigmoid vaginoplasty). A long enough follow-up period is important to detect long-term complications, some of which can be severe.

The mean length of the jejunum, ileum and sigmoid neovagina was comparable (respectively 9.8 cm, 15.7 cm and 12.3 cm). The mean length of the caecum neovagina was not reported. The mean width of the jejunum, ileum and sigmoid neovagina was also comparable (respectively 3.1 cm, 3.3 cm and 3.6 cm). The mean width of the caecum neovagina was not reported as well.

One of the most important reasons to undergo vaginoplasty is to achieve normal sexual function. These functional results were poorly described for all intestinal segments. The mean time between the operation and the first sexual intercourse was only reported in 3 studies on ileum vaginoplasty and in 5 studies on sigmoid vaginoplasty and was comparable (respectively 5.1 months and 5.9 months). The Sexual Function Index (FSFI) was only reported in 1 study on jejunum vaginoplasty and in 5 studies on sigmoid vaginoplasty and was comparable with a mean total score of respectively 27.5 and 27.6. These scores are similar to the scores of normal women. Generally, it can be said that most patients who had a partner were sexually active and described it as satisfactory. No significant differences in functional results were found between the bowel segments.

Intraoperative complication rates were very low (0% jejunum, 1.5% ileum, 0% caecum and 0.6% sigmoid) and were of a mild severity. All were detected and repaired immediately.

Postoperative complication rates were low (8.8% jejunum, 8.4% ileum, 18.2% caecum and 6.9% sigmoid). Vaginoplasty with sigmoid segments had the lowest postoperative

complication rate, while vaginoplasty with caecum segments had the highest postoperative complication rate. Most postoperative complications were of a mild severity and could be treated with conservative therapy. Severe postoperative complications occurred only in vaginoplasty with ileum and sigmoid segments.

Long-term complication rates were low (5.9% jejunum, 5.9% ileum, 9.1% caecum and 13.9% sigmoid). Most of these complications were of a mild severity. Moderate and severe complications only occurred in patients who underwent sigmoid vaginoplasty.

It is worth taking a closer look at some of the more common and/or severe complications of intestinal vaginoplasty.

Excessive vaginal discharge was a problem in most of the patients who underwent intestinal vaginoplasty which the patient found initially unpleasant and embarrassing. However, the vaginal discharge was of a transient nature and decreased 3 - 6 months postoperatively until it was no longer a source of concern. Only one case of persistent vaginal discharge was reported in a sigmoid neovagina (0.2%).

Malodor of the neovagina was only reported in three studies regarding vaginoplasty with sigmoid segments. A total amount of 8 patients mentioned this as a problem (1.2%). Malodor of the neovagina was not mentioned in studies regarding vaginoplasty with jejunum, ileum and caecum segments.

Stenosis of the neovagina was the main long-term complication in all intestinal segments (2.9% jejunum, 5.4% ileum, 6.1% caecum and 8.8% sigmoid) within the first postoperative year and was treated with dilation or surgical intervention. Several studies reported that patients were encouraged to use a vaginal dilator daily for a couple of weeks postoperatively, which may prevent stenosis of the neovagina.

Prolapse of the neovagina was a complication that occurred in all intestinal transplants except in caecum segments (2.9% jejunum, 0.5% ileum and 3.1% sigmoid) and was treated with vaginal resection of the prolapsed tissue and/or surgical repair. Several studies reported surgical fixation of the neovagina to numerous anatomical structures to prevent prolapse. These included the sacral promontory, the posterior wall of the pelvic cavity, the retropubic periosteum, the remnants of the Mullerian ducts, the uterosacral ligaments or the round ligament and the broad ligament of the uterus.

Diversion colitis is defined as a nonspecific inflammatory disorder that occurs in segments of the colon and rectum that are diverted from the fecal stream by surgery. Most patients with diversion colitis are asymptomatic; but, in a small proportion of patients, symptoms can significantly impact quality of life [69]. According to some authors, it is a common complication of vaginoplasty with sigmoid conduit and an important factor not to choose for intestinal vaginoplasty. However, only one case of diversion colitis was reported in a patient who underwent a sigmoid vaginoplasty (0.2%). This accentuates that diversion colitis is still a vaguely defined problem and that it should not be a reason to discard intestinal vaginoplasty.

One case of ulcerative colitis was reported in a patient who underwent sigmoid vaginoplasty (0.2%). She was treated with a total colectomy while the neovagina was treated topically.

None of the available literature mentioned carcinoma of the intestinal neovagina as a complication during follow-up. This shows that an increased risk to develop malignancy in patients who underwent intestinal vaginoplasty is minimal or absent.

One patient who underwent sigmoid vaginoplasty died as a result of renal failure and sepsis that led to multiple organ failure. This patient suffered from Bardet-Biedl syndrome. It is well known that in this syndrome renal disease has a considerable risk of progression to terminal renal failure. Preoperative infection, postoperative sepsis or obesity with immobility may lead to complications and precipitate renal failure as occurred in this patient [52].

CONCLUSION

Intestinal vaginoplasty is a reconstructive procedure for the vaginal canal and the vulva that can be performed in patients with congenital agenesis of the vagina, patients with disorders of sex development, male-to-female transgender patients and patients with a history of colpectomy. This reconstruction uses a free flap from the jejunum, ileum, caecum or sigmoid segment of the intestinal conduit.

Thirty publications with a total of more than 900 patients were analyzed for this literature review. Two major aspects about the design of these studies can be highlighted.

Firstly, there is a glaring contrast in the availability of literature among the different bowel segments. This does not benefit the comparison of results. There is a need for qualitative prospective studies on intestinal vaginoplasty, especially concerning jejunum, ileum and caecum segments.

Secondly, there is a need for a uniform representation of the functional results for all bowel segments. Sexual functioning is an important goal of intestinal vaginoplasty; however, the rendition of this outcome leaves much to be desired. A solution is the use of a standardized questionnaire for all patients undergoing intestinal vaginoplasty. An excellent example of this is the Female Sexual Function Index (FSFI) that is currently not being used very efficiently.

Nevertheless, intestinal vaginoplasty is associated with a low prevalence of intraoperative, postoperative and long-term complications in all bowel segments. Most reported complications were of a mild severity. Therefore, it can be concluded that intestinal vaginoplasty is a safe technique and that there is no superiority of one bowel segment over the other.

There is no clear answer to the question of which should be the bowel segment of choice. At present there is still no gold standard concerning intestinal vaginoplasty. Surgeons should make this decision based on their experience, taking into account the clinical background of the patient.

Finally, the role of pre- and postoperative psychological guidance should be emphasized. A multidisciplinary team of physicians is essential for a successful intestinal vaginoplasty.

REFERENCES

1. ACO Committee Opinion on Adolescent Health Care. ACOG Committee Opinion No. 355: Vaginal agenesis: diagnosis, management, and routine care. *Obstet Gynecol* 2006;108(6):1605–9.
2. Monstrey S, Van Landuyt K, Blondeel P, Hamdi M, Roche N. Chirurgische reconstructie van de vagina bij congenitale agenesie. *Tijdschrift voor Geneeskunde*. 2009; 65(16):738-743.
3. Guerrier D, Mouchel T, Pasquier L, Pellerin I. The Mayer-Rokitansky-Küster-Hauser syndrome (congenital absence of uterus and vagina) – phenotypic manifestations and genetic approaches. *J Negat Results Biomed*. 2006; 5: 1.
4. Rawat KS, Buxi T, Yadav A, Ghuman SS, Dhawan S. Large leiomyoma in a woman with Mayer-Rokitansky-Kuster-Hauser syndrome. *J Radiol Case Rep*. 2013 Mar 1;7(3):39-46.
5. Gonzalez EM, Prayson RA. Glioblastoma arising in a patient with Mayer-Rokitansky-Küster-Hauser syndrome. *J Clin Neurosci*. 2013 Oct;20(10):1464-5.
6. Bean EJ, Mazur T, Robinson AD. Mayer-Rokitansky-Küster-Hauser syndrome: sexuality, psychological effects, and quality of life. *J Pediatr Adolesc Gynecol*. 2009 Dec;22(6):339-46.
7. Hughes IA. Disorders of sex development: a new definition and classification. *Best Pract Res Clin Endocrinol Metab*. 2008;22:119–134.
8. Erdoğan S, Kara C, Uçaktürk A, Aydın M. Etiological Classification and Clinical Assessment of Children and Adolescents with Disorders of Sex Development. *J Clin Res Pediatr Endocrinol*. 2011 Jun; 3(2): 77–83.
9. Lee PA, Houk CP, Ahmed SF, Hughes IA; International Consensus Conference on Intersex organized by the Lawson Wilkins Pediatric Endocrine Society and the European Society for Paediatric Endocrinology. Consensus statement on management of intersex disorders. *International Consensus Conference on Intersex. Pediatrics* 2006;118:488-500.
10. Hughes IA, Houk C, Ahmed SF, Lee PA; LWPES Consensus Group; ESPE Consensus Group. Consensus statement on management of intersex disorders. *Arch Dis Child* 2006;91:554-563.
11. Ostrer H. Disorders of sex development (DSDs): an update. *J Clin Endocrinol Metab*. 2014 May;99(5):1503-9.

12. Speiser PW, White PC. Congenital adrenal hyperplasia. *N Engl J Med*. 2003 Aug 21;349(8):776-88.
13. Merke DP, Poppas DP. Management of adolescents with congenital adrenal hyperplasia. *Lancet Diabetes Endocrinol*. 2013 Dec;1(4):341-52.
14. Gottlieb B, Beitel LK, Trifiro MA. Androgen Insensitivity Syndrome. 1999 Mar 24 [Updated 2014 Jul 10]. In: Pagon RA, Adam MP, Ardinger HH, et al., editors. *GeneReviews®* [Internet]. Seattle (WA): University of Washington, Seattle; 1993-2015.
15. Pizzo A, Laganà AS, Borrielli I, Dugo N. Complete androgen insensitivity syndrome: a rare case of disorder of sex development. *Case Rep Obstet Gynecol*. 2013;2013:232696.
16. Purves JT, Miles-Thomas J, Migeon C, Gearhart JP. Complete androgen insensitivity: the role of the surgeon. *J Urol*. 2008 Oct;180(4 Suppl):1716-9.
17. Fotopoulou C, Neumann U, Klapp C, Lichtenegger W, Sehouli J. Long-term effects of neovaginal reconstruction with sigmoid loop technique on sexual function and self image in patients with gynecologic malignancies: results of a prospective study. *Gynecol Oncol*. 2008 Dec;111(3):400-6.
18. Hoffman KE, Horowitz NS, Russell AH. Healing of vulvo-vaginal radionecrosis following revascularization. *Gynecol Oncol*. 2007 Jul;106(1):262-4.
19. Heylens G, Verroken C, De Cock S, T'Sjoen G, De Cuypere G. Effects of Different Steps in Gender Reassignment Therapy on Psychopathology: A Prospective Study of Persons with a Gender Identity Disorder. *Journal of Sexual Medicine*, 11: 119–126.
20. Committee on Health Care for Underserved Women. Committee Opinion no. 512: health care for transgender individuals. *Obstet Gynecol*. 2011 Dec;118(6):1454-8.
21. Wroblewski P, Gustafsson J, Selvaggi G. Sex reassignment surgery for transsexuals. *Curr Opin Endocrinol Diabetes Obes*. 2013 Dec;20(6):570-4.
22. Selvaggi G, Ceulemans P, De Cuypere G, VanLanduyt K, Blondeel P, Hamdi M, Bowman C, Monstrey S. Gender identity disorder: general overview and surgical treatment for vaginoplasty in male-to-female transsexuals. *Plast Reconstr Surg*. 2005 Nov;116(6):135e-145e.
23. Pusic AL, Mehrara BJ. Vaginal reconstruction: an algorithm approach to defect classification and flap reconstruction. *J Surg Oncol*. 2006 Nov 1;94(6):515-21.
24. Eldor L, Friedman JD. Reconstruction of congenital defects of the vagina. *Semin Plast Surg*. 2011 May;25(2):142-7.

25. Nakhil RS, Creighton SM. Management of vaginal agenesis. *J Pediatr Adolesc Gynecol*. 2012 Dec;25(6):352-7.
26. Frank TR. The formation of an artificial vagina without operation. *Am J Obstet Gynecol* 1938;35:1053–1055.
27. Ingram JM. The bicycle seat stool in the treatment of vaginal agenesis and stenosis: a preliminary report. *Am J Obstet Gynecol*. 1981 Aug 15;140(8):867-73.
28. Lodovici O, Horibe K, Gemperli R, de Mendonça BB. Construction of the vagina by a non-surgical method. *Rev Hosp Clin Fac Med Sao Paulo*. 1989 Jan-Feb;44(1):40-2.
29. Bellati F, Calcagno M, Pastore M, Maffucci D, Celentano C, Boni T, Panici PB. Vaginal apex necrosis following use of the Frank method of dilation for vaginal agenesis due to Mayer-Rokitansky-Kuster-Hauser syndrome. *Int J Gynaecol Obstet*. 2009 Dec;107(3):254.
30. Zhu L, Zhou H, Sun Z, Lou W, Lang J. Anatomic and sexual outcomes after vaginoplasty using tissue-engineered biomaterial graft in patients with Mayer-Rokitansky-Küster-Hauser syndrome: a new minimally invasive and effective surgery. *J Sex Med*. 2013 Jun;10(6):1652-8.
31. McIndoe A. Treatment of congenital absence and obliterative conditions of the vagina. *Br J Plast Surg* 1950; 2: 254-267.
32. McCraw JB, Massey FM, Shanklin KD, Horton CE. Vaginal reconstruction with gracilis myocutaneous flaps. *Plast Reconstr Surg* 1976; 58: 176-183
33. Lilford RJ, Johnson N, Batchelor A. A new operation for vaginal agenesis: Construction of a neo-vagina from a rectus abdominis musculocutaneous flap. *Br J Obstet Gynaecol* 1989;96:1089-1094.
34. Wang X, Qiao Q, Burd A, Liu Z, Zhao R, Song K, Feng R, Zeng A, Zhao Y. A new technique of vaginal reconstruction with the deep inferior epigastric perforator flap: a preliminary report. *Plast Reconstr Surg*. 2007 May;119(6):1785-90
35. Smeets L, Hendrickx B, Teo TC. The propeller flap concept used in vaginal wall reconstruction. *J Plast Reconstr Aesthet Surg*. 2012 May;65(5):629-33.
36. Wee JT, Joseph VT. A new technique of vaginal reconstruction using neurovascular pudendal-thigh flaps: a preliminary report. *Plast Reconstr Surg*. 1989 Apr;83(4):701-9.
37. Selçuk CT, Evsen MS, Ozalp B, Durgun M. Reconstruction of vaginal agenesis with pudendal thigh flaps thinned with liposuction. *J Plast Reconstr Aesthet Surg*. 2013 Sep;66(9):e246-50.

38. Fedele L, Busacca M, Candiani M, Vignali M. Laparoscopic creation of a neovagina in Mayer-Rokitansky-Küster-Hauser syndrome by modification of Vecchietti's operation. *Am J Obstet Gynecol* 1994;171:268–9.
39. Baldwin JF. XIV. The Formation of an Artificial Vagina by Intestinal Transplantation. *Ann Surg.* 1904 Sep;40(3):398-403.
40. Erman Akar M, Özkan Ö, Özkan Ö, Colak T, Gecici O. Sexual function and long-term results following vaginal reconstruction with free vascular jejunal flap. *J Sex Med.* 2013 Nov;10(11):2849-54.
41. Trombetta C, Liguori G, Siracusano S, Bortul M, Belgrano E. Transverse retubularized ileal vaginoplasty: a new application of the Monti principle--preliminary report. *Eur Urol.* 2005 Dec;48(6):1018-23; discussion 1023-4.
42. Wu JX, Li B, Liu T, Li WZ, Jiang YG, Liang JX, Wei CS, Hu HO, Zhong CX. Eighty-six cases of laparoscopic vaginoplasty using an ileal segment. *Chin Med J (Engl).* 2009 Aug 20;122(16):1862-6.
43. Zhao YZ, Jiang H, Liu AT, Jiang DZ, Zhu XH, Qiu M, Zheng XM, Lin ZH, Yuan XB, Zhang JL. Laparoscope-assisted creation of a neovagina using pedicled ileum segment transfer. *World J Surg.* 2011 Oct;35(10):2315-22.
44. Abd El-Aziz S. Vaginal reconstruction using the ileocecal segment after resection of pelvic malignancy. *J Egypt Natl Canc Inst.* 2006 Mar;18(1):1-7.
45. Bridoux V, Kianifard B, Michot F, Resch B, Sibert L, Tuech JJ. Transposed right colon segment for vaginal reconstruction after pelvic exenteration. *Eur J Surg Oncol.* 2010 Nov;36(11):1080-4.
46. Khulpateea BR, Silver DF. A ten year experience of cecal neovagina procedures for the restoration of sexual function on a gynecology oncology service. *Gynecol Oncol.* 2014 Jul;134(1):150-3.
47. Abudaia J. Total Vaginal Replacement With Sigmoid Colon Experience at Gaza European Hospital. *PMJ - Palestinian Medical Journal* 2006; 2 (1): 71-3.
48. Cai B, Zhang JR, Xi XW, Yan Q, Wan XP. Laparoscopically assisted sigmoid colon vaginoplasty in women with Mayer-Rokitansky-Kuster-Hauser syndrome: feasibility and short-term results. *BJOG.* 2007 Dec;114(12):1486-92.
49. Cao L, Wang Y, Li Y, Xu H. Prospective randomized comparison of laparoscopic peritoneal vaginoplasty with laparoscopic sigmoid vaginoplasty for treating congenital vaginal agenesis. *Int Urogynecol J.* 2013 Jul;24(7):1173-9.

50. Carrard C, Chevret-Measson M, Lunel A, Raudrant D. Sexuality after sigmoid vaginoplasty in patients with Mayer-Rokitansky-Küster-Hauser syndrome. *Fertil Steril*. 2012 Mar;97(3):691-6.
51. Djordjevic ML, Stanojevic DS, Bizic MR. Rectosigmoid vaginoplasty: clinical experience and outcomes in 86 cases. *J Sex Med*. 2011 Dec;8(12):3487-94.
52. Ekinçi S, Karnak I, Ciftci AO, Senocak ME, Tanyel FC, Büyükpamukçu N. Sigmoid colon vaginoplasty in children. *Eur J Pediatr Surg*. 2006 Jun;16(3):182-7.
53. Fahmy MAB, Al Abeissy HAHM, Abdalla MM. Applicability of Sigmoid Colon Graft for Vaginal Replacement (Colovaginoplasty) at Young Age. *Surgical Science*, 2011, 2, 422-426.
54. Garcia-Roig M, Castellan M, Gonzalez J, Gorin MA, Cruz-Diaz O, Labbie A, Gosalbez R. Sigmoid vaginoplasty with a modified single Monti tube: a pediatric case series. *J Urol*. 2014 May;191(5 Suppl):1537-42.
55. Imperato E, Alfei A, Aspesi G, Meus AL, Spinillo A. Long-term results of sigmoid vaginoplasty in a consecutive series of 62 patients. *Int Urogynecol J Pelvic Floor Dysfunct*. 2007 Dec;18(12):1465-9.
56. Kapoor R, Sharma DK, Singh KJ, Suri A, Singh P, Chaudhary H, Dubey D, Mandhani A. Sigmoid vaginoplasty: long-term results. *Urology*. 2006 Jun;67(6):1212-5.
57. Khen-Dunlop N, Lortat-Jacob S, Thibaud E, Clément-Ziza M, Lyonnet S, Nihoul-Fekete C. Rokitansky syndrome: clinical experience and results of sigmoid vaginoplasty in 23 young girls. *J Urol*. 2007 Mar;177(3):1107-11.
58. Kim SK, Jeong JO, Kwon YS, Lee KC, Park KJ, Jung G. Laparoscopic rectosigmoid flap vaginoplasty. *J Plast Surg Hand Surg*. 2011 Sep;45(4-5):226-31.
59. Li S, Sun C, Shi B, Li M, Liu L. Laparoscopic vaginoplasty using a sigmoid graft through the umbilical single-incision hybrid transperineal approach: our initial experience. *J Laparoendosc Adv Surg Tech A*. 2014 May;24(5):354-8.
60. Nowier A, Esmat M, Hamza RT. Surgical and functional outcomes of sigmoid vaginoplasty among patients with variants of disorders of sex development. *Int Braz J Urol*. 2012 May-Jun;38(3):380-6; discussions 387-8.
61. Rawat J, Ahmed I, Pandey A, Khan TR, Singh S, Wakhlu A, Kureel SN. Vaginal agenesis: Experience with sigmoid colon neovaginoplasty. *J Indian Assoc Pediatr Surg*. 2010 Jan;15(1):19-22.

62. Shen Y, Wang G, Xiong Z, Tao K, Wang Z. Laparoscopic sigmoid vaginoplasty in women with Mayer-Rokitansky-Kuster-Hauser syndrome. *Front Med China* 2009 Sep;3(3): 347-351.
63. Yin D, Wang N, Zhang S, Huo N, Xiao Q, Ling O, Lu Y, Wei H. Radical hysterectomy and vaginectomy with sigmoid vaginoplasty for stage I vaginal carcinoma. *Int J Gynaecol Obstet.* 2013 Aug;122(2):132-5.
64. Zhong CX, Wu JX, Liang JX, Wu QH. Laparoscopic and gasless laparoscopic sigmoid colon vaginoplasty in women with vaginal agenesis. *Chin Med J (Engl).* 2012 Jan;125(2):203-8.
65. Burgu B, Duffy PG, Cuckow P, Ransley P, Wilcox DT. Long-term outcome of vaginal reconstruction: comparing techniques and timing. *J Pediatr Urol.* 2007 Aug;3(4):316-20.
66. Karateke A, Haliloglu B, Parlak O, Cam C, Coksuer H. Intestinal vaginoplasty: seven years' experience of a tertiary center. *Fertil Steril.* 2010 Nov;94(6):2312-5.
67. Lima M, Ruggeri G, Randi B, Dòmini M, Gargano T, La Pergola E, Gregori G. Vaginal replacement in the pediatric age group: a 34-year experience of intestinal vaginoplasty in children and young girls. *J Pediatr Surg.* 2010 Oct;45(10):2087-91.
68. Wright C, Hanna MK. Thirty-six vaginal constructions: lessons learned. *J Pediatr Urol.* 2014 Aug;10(4):667-71.
69. Shen, B. Diversion colitis. In: UpToDate, Post, TW (Ed), UpToDate, Waltham, MA, 2015.